Nomenclatura dos ossos

Esqueleto Apendicular

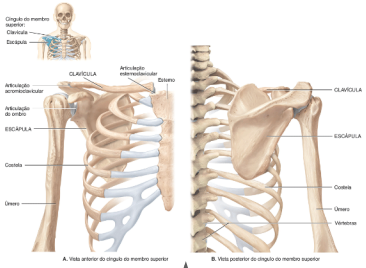

Membros Superiores (MMSS)

Membros inferiores (MMII)

CLAVÍCULA - ESCÁPULA

ÍLIO
ÍSQUIO
PÚBIS

Cìngulo do membro superior – úmero (Braço) – Ulna e radio (antebraço) – Ossos do carpo – metacarpos - falanges (mãos)

Quadril – fêmur (Coxa) – Patela (Joelho) – Tíbia e fíbula (Perna) – ossos do tarso – metatarsos – falanges (Pé)

ESCAFÓIDE
SEMILUNAR
PIRAMIDAL
PISIFORME
TRAPÉZIO
TRAPEZÓIDE
CAPITATO
HAMATO

PROXIMAL -
MÉDIA - DISTAL

TÁLUS
CALCÂNEO
NAVICULAR
CUNEIFORME
(medial,
intermédio,
lateral)
CUBÓIDE

PROXIMAL -
MÉDIA - DISTAL

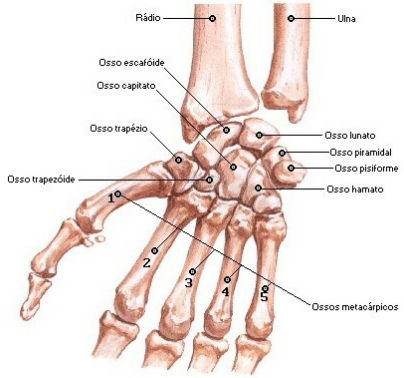

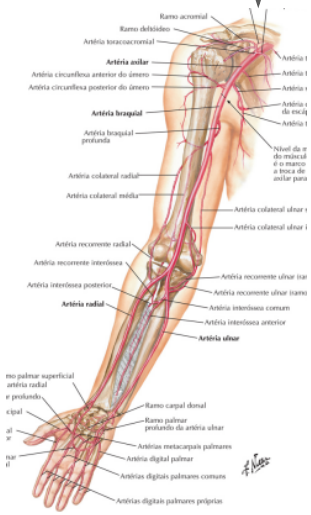

*TODAS AS IMAGENS FORMA RETIRADAS DE NETTER, 2019.